



PATIENT

Oliver Bai

PRESENTING CLINICAL SIGNS

History: Patient seems to pant after playing or if patient does a lot of activity.

SPECIES

Feline

ECHOCARDIOGRAM FINDINGS

2D, m-mode, color flow and doppler imaging is available. The left ventricular wall is normal in dimension. There is a mildly hyperechoic endocardium. The papillary muscles are normal. The left atrium is normal in size. The right heart and MPA appear normal. The mitral valve is normal in structure and mobility. Blood flow through both the LVOT and RVOT is normal in velocity. No obvious congenital shunts. No pleural or pericardial effusion seen. No obvious cardiac tumors.

BREED

DSH

CARDIAC CHART

SEX

Male Neutered

AGE

1 year

WEIGHT

6.7lbs

INTERPRETED BY

Maggie Machen Lamy,
DVM, DACVIM
(Cardiology)

FELINE CARDIAC PARAMETERS	BODY WEIGHT (kg)	HR (BPM)	IVSd (cm) (Moise, Pipers)	LVIDd (cm) (Moise, Pipers)	LWVd (cm) (Moise, Pipers)	FS (%)	EF (%)
NORMAL PARAMETER	-----	150-240	0.35-0.55	<2 (mean 1.5)	3.5-0.55	35-67	80-100
PATIENT	3.0	124	0.46	1.4	0.45	55	92
FELINE CARDIAC PARAMETERS	LA/AO (Boon)	LA/AO HEART BASE (Swe) (Abbott)	LA 2D short axis Base view (cm) (Abbott)		LVOT VEL (m/s)	RVOT VEL (m/s)	E max (m/s)
NORMAL	<1.5	<1.3	<1.2		<1.6	<1.3	<0.9
PATIENT	1.4	1.0	1.0		1.0	1.1	NM

**Note: All measurements based upon multi-modal images and methods. An average value is reported.*
Adapted from June Boon, Veterinary Echocardiography, 1998
Abbott J & MacLean H JVIM 2006;20: 111-119, Moise et al. Am J Vet Res 47:1476, 1986. Pipers et al. Am J Vet Res 40:882, 1979.

IMAGING PERFORMED BY

Kelly Vazquez, CVT

INTERPRETATION OF THE FINDINGS & FURTHER RECOMMENDATIONS

Overtly normal cardiac structure and function. The LV wall thickness is normal and there is no evidence of elevated left atrial pressure. No obvious congenital shunts or defects are visualized; however, it is important to note that small abnormalities are easily missed particularly in juvenile kittens.

HOSPITAL NAME

Animal General on Hudson

Given these findings, no medications are indicated. No obvious structural cause for exercise intolerance is seen. Should the symptom worsen/persist, or a murmur be ausculted, referral is recommended.

REFERRING VET

Dr. Tierney

No cardiac contraindication for general anesthesia.

INVOICE

26990

Recommend recheck echocardiogram should a murmur, gallop or clinical signs of cardiac compromise be noted in the future.

DATE

10/19/22



PATIENT

Oliver Bai

SPECIES

Feline

BREED

DSH

SEX

Male Neutered

AGE

1 year

WEIGHT

6.7lbs

INTERPRETED BY

Maggie Machen Lamy,
DVM, DACVIM
(Cardiology)

**IMAGING
PERFORMED BY**

Kelly Vazquez, CVT

HOSPITAL NAME

Animal General on
Hudson

REFERRING VET

Dr. Tierney

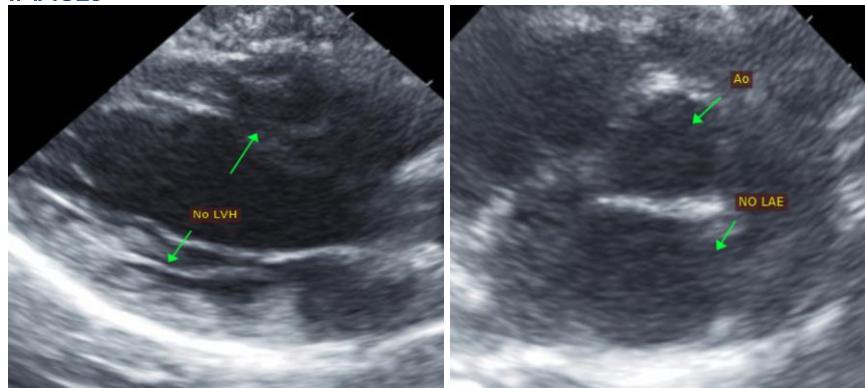
INVOICE

26990

DATE

10/19/22

IMAGES



The information and recommendations provided are based on the images presented by the referring veterinarian. No evaluation can be communicated regarding pathology that was not visible in the image/video clips provided.

Thank you for this referral. This report was generated using transcription software, and minor dictation errors may be present. If the clinical or image interpretation does not parallel your findings or if I can be of any further assistance, please contact me.

Maggie Machen Lamy, DVM
Diplomate of the American College of Veterinary Internal Medicine (Cardiology)
info@sonopath.com